

## Patient Experience with ViviGen® Cellular Bone Matrix in Cervical Revision Surgery

Kennedy Yalamanchili, MD, FACS  
Delaware Neurosurgical Group  
Christiana Care Health System  
Newark, DE

### Introduction

A 44-year-old Caucasian female with a 60-pack per year smoking history and a complicated history of cervical disc surgery for neck and radicular arm complaints presented after 3 prior surgeries conducted by a spine surgeon from another Health System.

### Surgical History

Her previous surgical history included a C5-6 anterior cervical discectomy and fusion in October 2008. A year later the patient underwent a revision posterior cervical surgery at with supplemental spinous process autograft and posterior instrumentation a year later. The patient did well following this surgery.

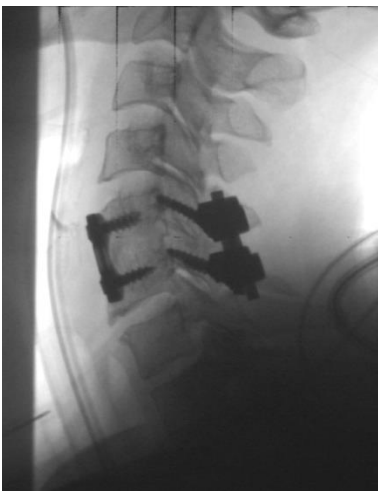


Figure 1. Lateral X ray of C5-6 construct following the addition of posterior instrumentation.

Three years later she developed recurrent neck and radicular arm complaints with testing showing subjacent disc disease at C6-7 and C7-T1. After failing to respond to conservative treatment, she underwent an additional surgery provided by the same spine surgeon in September 2012, involving an anterior cervical reexploration, removal of C5-6 instrumentation, and C6-7/C7-T1 anterior discectomy and fusion. This surgery was again complicated by pseudoarthrosis.

### Surgical Procedure

The patient presented to my practice with severe disabling neck and bilateral radicular arm complaints of pain and numbness. She reported subjective loss of strength in both hands, though no clear motor deficit was demonstrated along with depressed reflexes in both arms. An EMG confirmed lower cervical radiculopathy in a C6-7 distribution. A CT showed a reasonable fusion at C5-6, though limited bone healing was seen at that level despite the supplemental posterior cervical surgery and clear pseudoarthrosis at C6-7 and C7-T1.

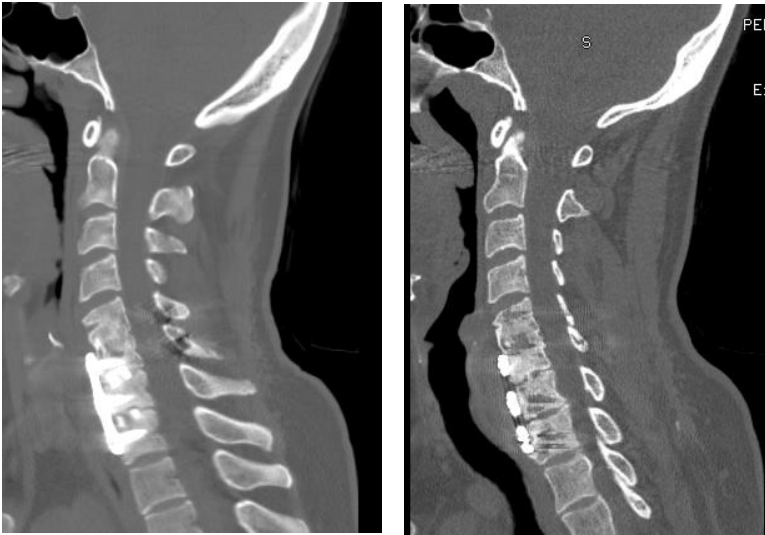


Figure 2. Sagittal CT of pseudoarthrosis at C6-7 and C7-T1.

In September 2014, the patient underwent a posterior cervical revision from C5-T1 with laminoforaminotomies and fusion with local autograft augmented with 5 cc of ViviGen® Cellular Bone Matrix and was instrumented with the MOUNTAINEER® OCT Spinal System.

### Patient Results

The patient showed improvement in her VAS scores from 10 to 5. Despite persisting symptoms her CT's at 6 months and 13 months following surgery showed solid fusion from C5-T1.

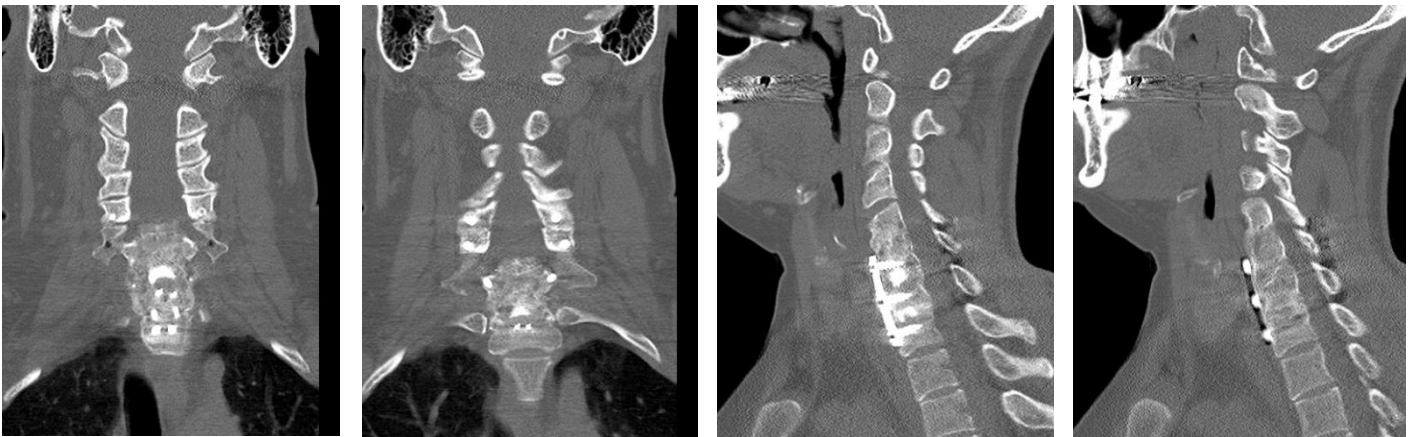

Figure 3. CT at 6 month follow up showing fusion from C5-T1.

### About ViviGen® Cellular Bone Matrix

ViviGen comprises cryopreserved live, viable bone cells within a corticocancellous bone matrix and demineralized bone. ViviGen is processed from donated human tissue and is intended for repair, replacement, or reconstruction of musculoskeletal defects. ViviGen contains viable cells that are committed to produce bone in concert with the osteoconductive scaffold and osteoinductive signals naturally found within the demineralized bone<sup>1</sup>.

1. Data on file LifeNet Health

ViviGen is a registered trademark of LifeNet Health

©DePuy Synthes 2016. All rights reserved.

DSUS/SPN/1015/1048e 7/16 EX-16-084